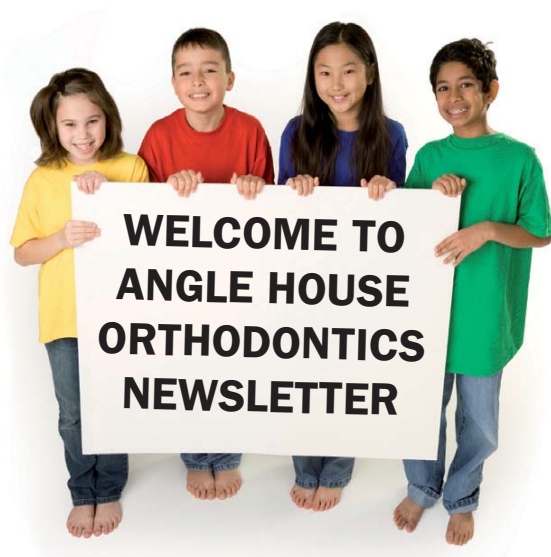



It's 2010! Happy New Year. For the new decade, British Orthodontic Society is launching the first ever National Orthodontic Week on 22nd - 28th March, 2010 at the National Portrait Gallery. The aim is to highlight the expertise of the orthodontic profession via radio, TV and local media in educating patients about benefits of improved dental health and appearance.

To mark this week Angle House Orthodontics are offering **adult** patients a **FREE** orthodontic consultation. We would like to work with you on patients with restorative and periodontal problems who may need a multidisciplinary approach. For more information please visit our website. You can refer your patients via our paper referral forms or online.



Well it's almost 4 years since the start of the new contract and we hope this newsletter will provide you with an update. We would also like to thank you for referring your patients to us. We respect and appreciate that you are trusting us with your patients' orthodontic care and we are grateful for your continued support during their treatment.

All patients referred to us under the age of 18 years are still entitled to an orthodontic assessment on the NHS. Funding for treatment is offered to patients with moderate to severe need based upon Index of Treatment Need (IOTN) as before. We continue to provide functional appliances, thumb deterrent devices as well as complex orthodontic treatment including correction of impacted canines and hypodontia management on the NHS. Those patients who fall below the cut off point (IOTN < 3.6) are offered treatment independent of the NHS, where appropriate.

We charge independent fees for orthodontic treatment for children under 18 years from £1600 as opposed to an average cost of over £3000 for private fees. These patients will receive the same treatment as they would under the NHS and would usually be seen during school time. We also offer options in payment plans which means parents can pay in instalments or arrange an interest free loan. We realise that there are some parents who cannot afford private payment but hope this independent fee structure will make it easier for many of these patients whose treatment is not funded on the NHS.



We make the parents aware of these changes once we receive your referral. We request that you continue to refer all patients as you have in the past. On-line referral service is now popular in addition to our existing paper one. You can log onto our website and click the referring dentist icon. www.anglehouseorthodontics.co.uk



Adult Orthodontics- 'Weapons of mastication'



Anyone who watched the Grand National last year will remember BBC presenter Clare Balding teasing the winning jockey, Liam Treadwell about the state of his laughing gear! She burred "He hasn't got the best teeth in the world" to him and everyone watching the Grand National. The jockey looked shocked and embarrassed. Maybe like many British men he probably just didn't know he has a problem with his smile. You may remember Tony Blair, by the end of his leadership, his lower central incisor seemed to have receded further back into his mouth. The Times article followed "he should have spent more time worrying about his own weapons of mastication".

We have seen a dramatic rise in adult orthodontics and British men have also been part of this. The development of discreet orthodontic appliances like Radiance clear ceramic appliance system and lingual Incognito system, makes orthodontic treatment option more appealing to adults.

Here's what Alex said after his treatment which involved a multidisciplinary approach with his referring dentist providing the restorative aspect and Angle House providing the orthodontics, "The experience has literally changed my life. I never believed I could have perfect teeth but now I'm as close as I can hope to be. I didn't realise the impact it would have on my life, so many people have noticed the change and commented on it. I had a combination of lingual orthodontics, teeth whitening and some cosmetic crowns. I wouldn't hesitate to recommend changing your teeth. It might just change your life!"

If you would like to discuss multidisciplinary treatment for any of your adult patients please do not hesitate to contact us. The patients can also take advantage of a FREE consultation over the National Orthodontic Week this March.

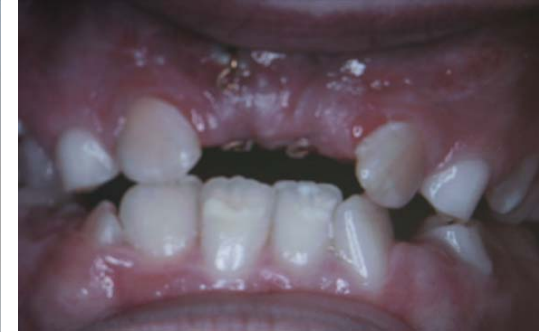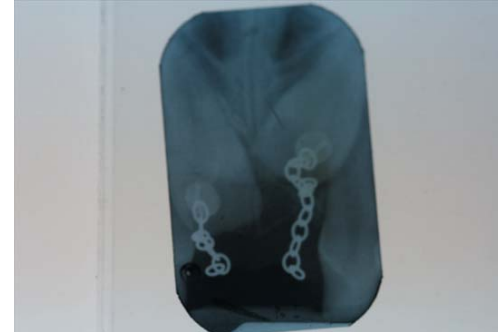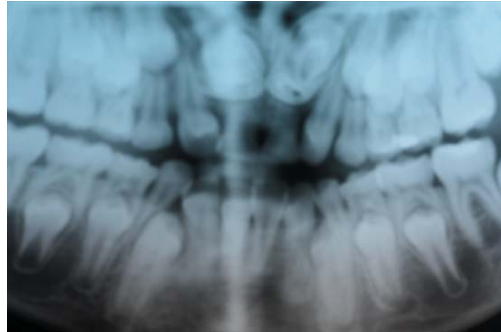
Case Report -

Unusually stubborn impacted upper central incisor

Rebecca was referred to us by her dentist who noted her central incisors had failed to erupt. Examination showed supernumeraries in this region which were speedily extracted and both central incisors bonded with a gold chain (see figs 1,2&3). The oral surgeon reported that the supernumeraries were 'extraordinarily shaped, much more like premolars and really quite bulky'.

REBECCA'S XRAYS / PHOTOS Fig. 1 2 & 3

Orthodontic treatment was commenced with a removable appliance to open space to accommodate both central incisors.




UR1 erupted within 6 months of surgery. As the patient was in mixed dentition we awaited further dental development before progressing onto fixed appliances. Almost 2 years later despite applying traction UL1 was still unerupted! Radiographs did not reveal further supernumeraries. As a last option we referred her back to the oral surgeon requesting him to surgically luxate UL1.

In addition to mobilising it he created a bony channel along which the tooth could erupt. Light traction was commenced 2 weeks after surgery. Gradually this tooth erupted fully and eventually the patient's fixed appliances debonded. Obviously the family are ecstatic and the tooth remains level with adjacent incisors for now. Rebecca's treatment was undertaken on the NHS and took over 4 years.




For her it means, as a teenager she does not have to put up with a gap in the front of her mouth or wear a denture should the ankylosed tooth have been removed. The bone level and gingival margin are maintained. We highlight this case as perseverance with prolonged treatment paid off for her.

It is sometimes difficult at the onset to predict orthodontic outcome for individual cases but with good planning, patient compliance and parental support the majority of patients will achieve a greatly improved result. Obviously retention is essential and all our patients are requested to maintain long term retention. We would like to thank Rebecca for being such a great patient and her oral surgeon Mr Peter McDermott for his expertise.




National
Orthodontic
Week

Book Free Consultation
22nd to 28th March 2010
Adults only



working closely with



BRITISH
ORTHODONTIC
SOCIETY

And finally

Angle House Chingford moved to new premises which was opened by the Right Honourable MP, Mr Iain Duncan Smith, last summer.



www.anglehouseorthodontics.co.uk



INVESTOR IN PEOPLE

Angle House Orthodontics
237 Hall Lane
Chingford
London E4 8HX
Tel: 020-8559 4272

Angle House Orthodontics
Crouch End Health Centre
45 Middle Lane
Crouch End, N8 8PH
Tel: 020-8348 8220

Angle House Orthodontics
5th Floor, Elizabeth House
54-58 High Street
Edgware HA8 7EJ
Tel: 020-8952 4596

Angle House Orthodontics
38 Harington Terrace
Gt. Cambridge Road
Edmonton N18 1JX
Tel: 020-8803 0388

Angle House Orthodontics
39 The Ridgeway
Enfield,
Middx. EN2 8PD
Tel: 020-8367 3441